

Clinical Case

Digital Dynamization Strategies in Orofacial Harmonization Clinical Case

Angela Herrera*

Prosthodontics and Occlusion, Faculty of Dentistry, University of Carabobo (UC), Venezuela

*Corresponding author: Angela Herrera, Faculty of Dentistry, University of Carabobo (UC), Venezuela

Received: June 22, 2022; Accepted: July 04, 2022; Published: July 07, 2022

Abstract

The harmony between the teeth and their adjacent structures is decisive in the construction of a smile with esthetics and function. Objective: to present a clinical case of a 58-year-old patient-client where the use of a digital tool to complement the diagnosis and treatment plan, and at the same time the combination of non-surgical esthetic facial and dental procedures, is evidenced. Methodology: after the corresponding evaluation, with prior approval of the informed consent, techniques were performed for each third. Results: the client-patient recovered his self-esteem with the reorganization of his tissues with the methods applied to improve his smile. Conclusion: It is concluded that the combination of techniques in orofacial harmonization together with a correct facial analysis, and the use of the DENTAL APP as a tele odontology tool allowed us to verify that it generates accessibility to information, promotes mutual feedback (client-patient and dentist/dentist and client-patient) for the diagnosis and future treatment plan, in order to achieve an intelligent orofacial beauty.

Keywords: Smile, Harmonization, Orofacial, Tele odontology, Beauty

Introduction

The arrangement of the dental arches is fundamental, since they influence facial appearance when units are lost and there are gaps, signs of aging and facial asymmetry appear, therefore, it is a requirement that the face be evaluated as a whole. In this perspective, dentistry procedures are in search of achieving the facial beauty of the dental patient-client, defined by Herrera & Aguirre [1] as the user who requests and receives oral health services that include the diagnosis, treatment and prevention of diseases of the stomatognathic apparatus to accommodate the altered functions, and whose key to the good management of the relationship with him/her is the ability of the dentist to manage his/her needs and expectations with respect to the product or service that is offered. This, in order to obtain the symmetry, harmony and balance of the desired face. Traditional stomatology has as its main focus the intraoral region and to provide all these characteristics, its configuration must be determined not only by the dental elements, but also by the bones, muscles, adipose tissue and skin.

Hence, dentistry is a great ally in the restoration of function and well-being, in addition to the search for a smile that is in harmony with a balanced face, which is defined as beauty and joviality. That is why the established techniques of routine use have already had a great impact on the composition of this facial harmony, such as, for example, the augmentation and anatomization of teeth promoted by restoration techniques, as well as the modification of the facial profile, with orthodontic movements and oral-maxillofacial surgeries, with the certainty that the intraoral modifies the extra oral.

For this reason, the profession has currently expanded by integrating with other disciplines to extend its action to the surrounding tissues in a non-surgical way, having new angles of observation that have the ability to provide even more tools in the assessment of facial aesthetics. Therefore, more and more people are learning to contemplate the face as a whole, giving prominence to the smile, which is one of the most dynamic and striking expressions presented by the human being.

In this sense, it should be noted that the face is the part of the body that is most directly related to the world and it is through it that the individual expresses himself. Therefore, changes in biopsyoemotional behavior are a consequence of the innumerable modifications that occur in it, since character and form have a direct influence on each other [2]. Hence, the exhaustive facial analysis based on the facial thirds converges today in the techniques of orofacial harmonization, which together with the use of digital dynamization strategies confer benefits before a face-to-face approach, since a previous evaluation of the client-patient can be carried out, by systematizing the process through the registration of a video, of his data and front and profile photographs; This will presumably lead to reveal techniques and methods that will be planned for their future treatment plan, in addition to optimizing the managerial functionality of dental organizations.

Orofacial Harmonization

In this perspective, the latest trends in techniques and methods on rejuvenation and facial harmony, have a new direction, a new paradigm, which is called orofacial harmonization, which is based on

a set of actions aimed at restoring the aspects of balance, beauty and youthfulness covering the treatment of teeth, skin, muscles, muscle-aponeurotic system, fat and even bone tissue; taking into account that the etiology can be linked to aging, which is a multiple process that includes extrinsic and intrinsic factors that affect not only one tissue, but multiple facial structures and leave sequels of different nature [3].

Thus, dentistry has acquired the right to act in the region between the hyoid bone and the hairy area of the forehead, as well as between the lines that pass over the anatomical point of the tragus on each side of the face [2,4]. Thus, it has implications for facial appearance rejuvenation treatments in order to provide a natural appearance and to achieve conformity to the needs and desires of the client-patients. Taking into account the latest discoveries related to harmony, symmetry and orofacial aesthetics, which shows that today it is possible to complete aesthetic treatments with the necessary refinement, so it is possible to make small adjustments, correct imperfections, minimize and avoid the signs of aging, as well as to provide the aesthetic and functional balance of the face [5].

Digital Dynamization Strategies

For the reasons described above, it is imperative that today's dentists acquire management skills that will enable them to manage the expectations and needs of clients and patients as an intangible relational asset, taking into account the fundamental bioethical principles that are universally recognized by the professional codes in dentistry.

It should be noted that understanding these needs through systematic feedback will contribute to the management of a long-term mutual working relationship and, at the same time, will enhance loyalty, so that its constant monitoring is and will be fundamental in any strategic planning of any dental organization. From this perspective, the use of one of the dynamization strategies, specifically CRM (customer relationship management), has special emphasis on the relationship that exists between the company and the client or a supplier (dentist/client-patient), since it includes software, hardware, communication networks, among others [6]. It should be emphasized that the client's personalization must be present, that is, to discover and know the client in detail, with the purpose of achieving both the approach and the interpretations that the client-patient has regarding the identity he/she intends to achieve through the service he/she seeks to hire.

In particular, tele odontology, which is supported by telemedicine, creates a way of making distant consultations possible, sharing digital information such as images, cooperative work, documents, x-rays, among others [7]. In other words, the use of electronic information, image and communication technologies, which include interactive audio, video and data communications, as well as storage and forwarding technologies, facilitates, contributes to and supports the provision, diagnosis, consultation, transfer of dental information and education on dental care. This has increased significantly with the emergence of the Covid-19 pandemic and the new SARS-CoV2 coronavirus (Severe acute respiratory syndrome coronavirus 2), making it clear that they are not substitutes for face-to-face

consultation, but a support manager in the management of dental patient-clients.

This being so, it is evident that today there is an increase in the search for tools such as health, wellness and beauty Apps that allow interaction and optimization of remote care with the client-patient, being used as the first line of action in cases where face-to-face contact is not possible [8]. For this reason, in this article we explain that the use of one of the dynamization strategies called DENTAL APP created by the author for the specialty of Orofacial Harmonization, approved today in Brazil and Venezuela, is a complementary tool to allow the professional to immerse himself in a world full of possibilities with a wide range of information and thus produce more satisfaction and meet the expectations of his client-patients.

It should be noted that it is a data repository, that is, a centralized space where digital information is stored, organized, maintained and disseminated, which will be used by the dentist-assembler to carry out an exhaustive preliminary analysis that will lead to a future diagnosis. Therefore, it should be noted that it is part of an information management system (IMS) that is defined as a group of interrelated components that work together towards a common goal by accepting inputs and generating outputs in an organized transformation process [9]. In short, its implementation in this new area of dentistry is intended for the purpose of managing the dental client-patient based on the analytical balance from the orofacial harmonization, through the fusion of the field of dentistry and facial aesthetics, conferring benefits at the time of having an approach to perform a clinical evaluation of the client-patient, after the systematization of the process obtained through the registration of all the data requested. Thus, the decision making of the managers has to be the most productive and efficient [10].

Case Presentation

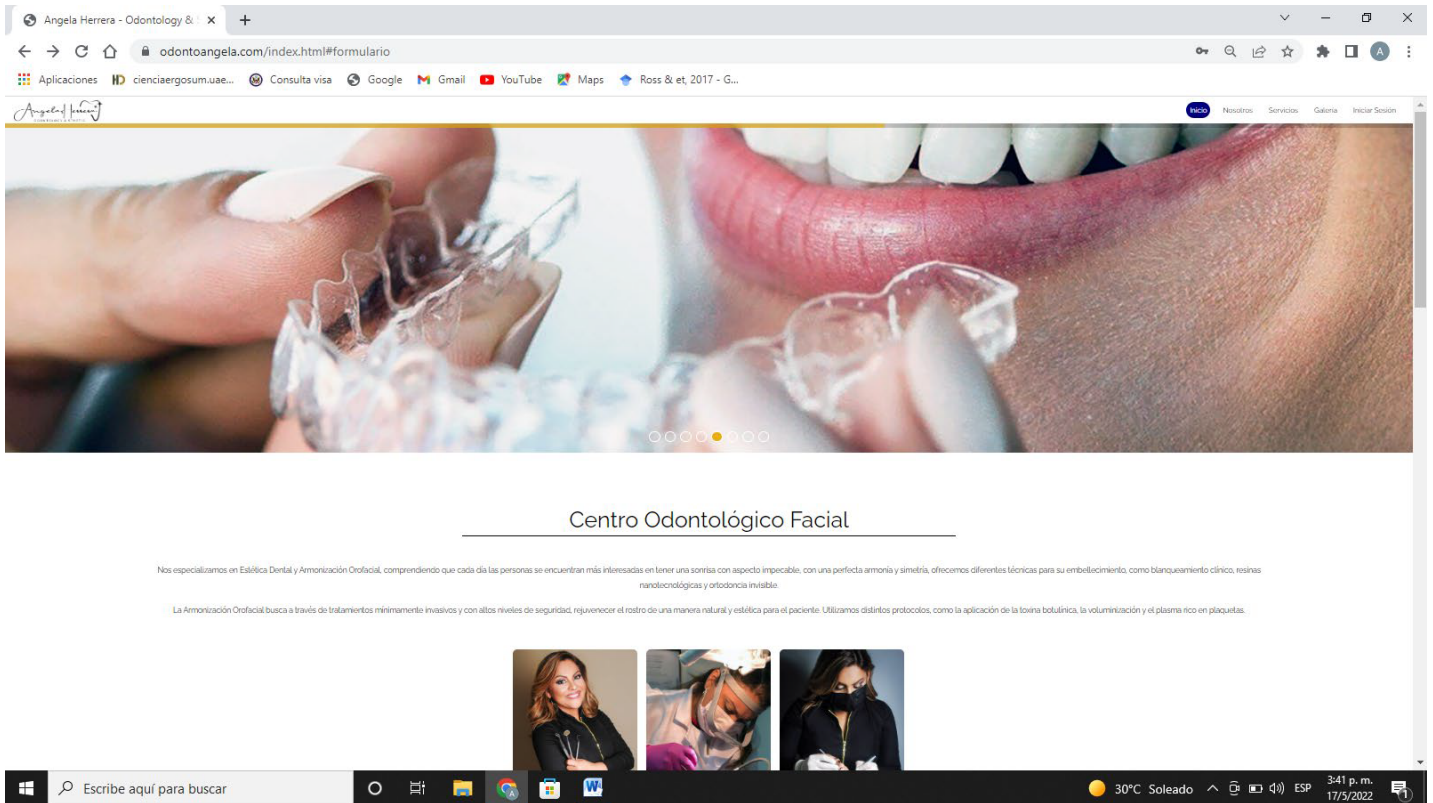
The 58-year-old female dental client-patient sent through the digital tool: DENTAL APP (Figure 1) images of her face and smile along with a video referring that "she wants to improve her teeth, her skin and of some sagging structures that she does not like on her face".

Image Exploration

We proceeded to verify the information received (Figure 2), evaluating the representations obtained with the support of a rubric originated where the characteristics present in each facial third and in her smile were determined.

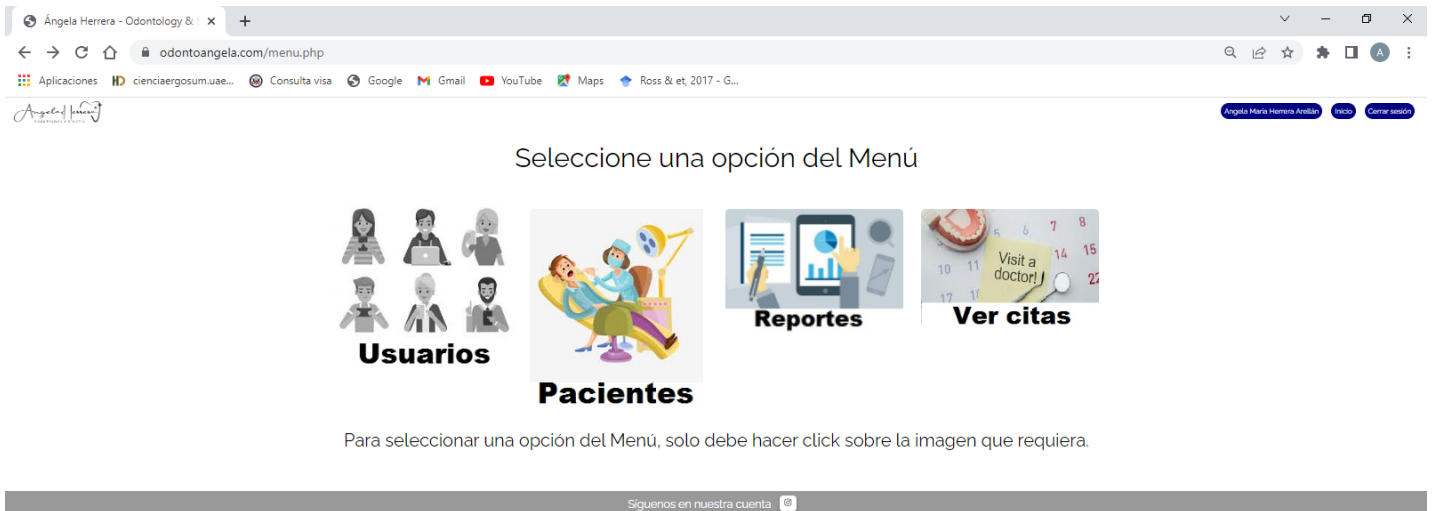Diagnostic Summary and Treatment Plan

In order to build the treatment objectives we determined with the digital evaluation (Figure 3) the presence of a mesofacial or misoprostol somatotype, among its clinical signs in the upper facial third: frontal rhytides, rhytides in the orbicularis oculi, descent of right and left temporal fatty compartment, upper panniculopathic dermatochalasis (Roof). In the middle facial third: presence of nasojugal sulcus, panniculopathic descent of the nasolabial area, descent of the tip of the nose. In the lower facial third: descent of the lateral supramandibular and lower mandibular compartment, loss of definition of the mandibular contour, inferior displacement of the floor



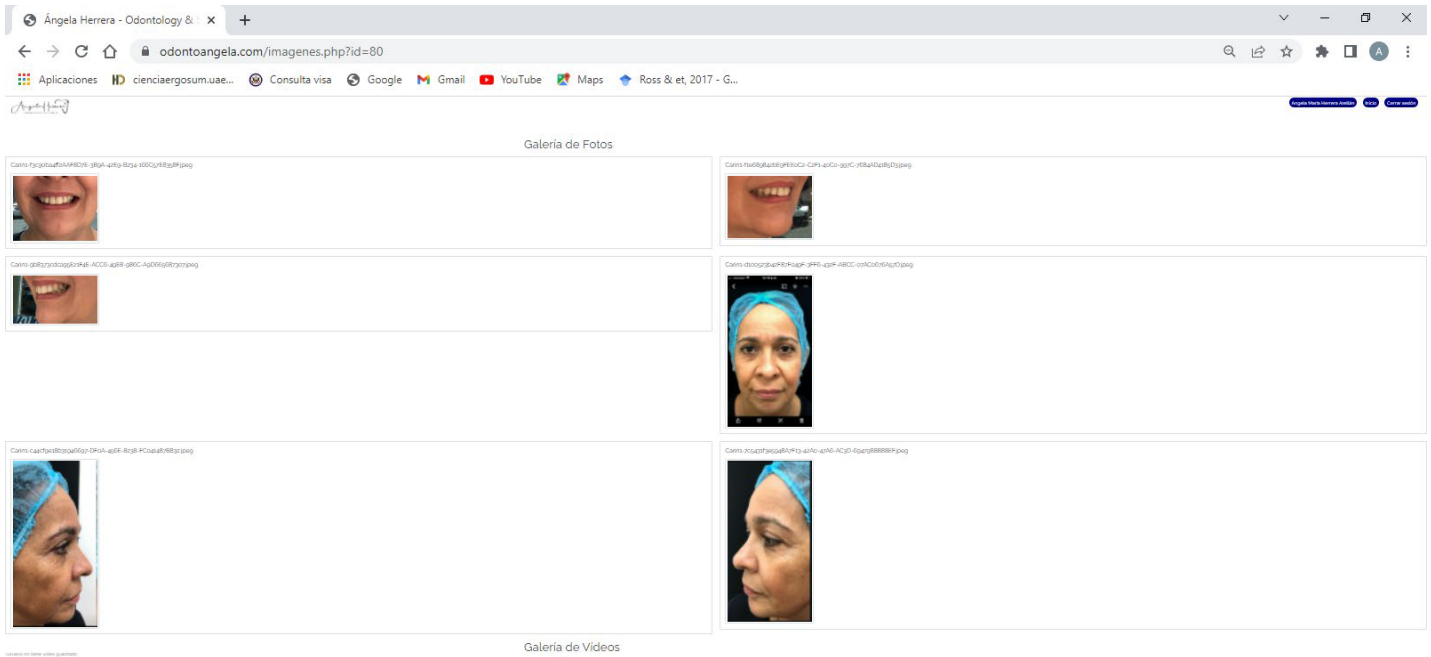
Source: Own elaboration (2022)

Figure 1: Dental App entrance.



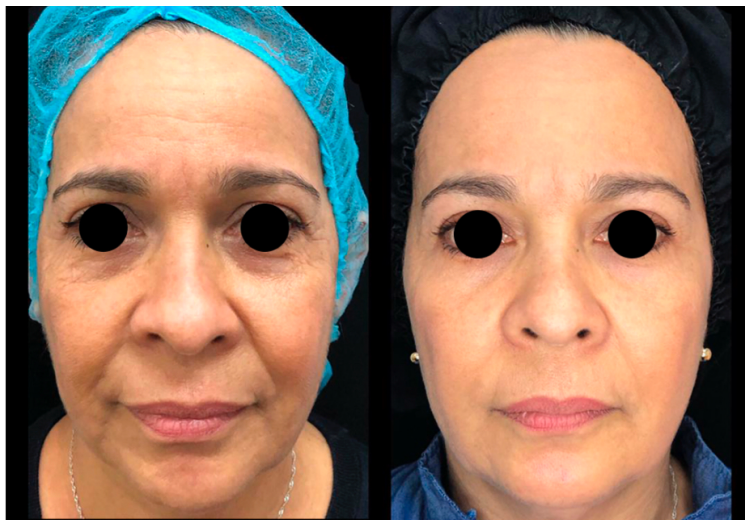Source: Own elaboration (2022)

Figure 2: Menu to obtain data from client-patients for verification of the information received.



Source: Own elaboration (2022)

Figure 3: Verification of the images requested from the registered patient-client.



Source: Own elaboration (2022)

Figure 4: Before and after the application of Orofacial Harmonization techniques.

of the mouth. And finally, among the dental characteristics: presence of anterosuperior veneers and anterior deep bite. Consequently, when complemented with her face-to-face clinical evaluation, the characteristic signs evidenced in the digital evaluation were verified and the following were determined as definitive diagnosis: active aging, deflation and lipomatosis.

Afterwards, with prior approval of the informed consent of the client-patient, the treatment planning was carried out using a combination of techniques or common procedures in orofacial

harmonization with the objective of rejuvenating and restructuring each facial third, which included dermal redensification with High Intensity Focused Ultrasound (HIFU) in the three thirds and floor of the mouth, redensification of the right and left temporal fossa with Organic Silicon and Dimethylaminoethanol (DMAE), neuromodulator of the upper third (forehead, glabella and orbicular lines) with Botulinum Toxin (BOTOX), five (5) sessions of Facial adipostructure which is a technique aimed at the panniculopathic reorganization of the facial fat compartments according to their

structure without removing them [11]. Next, collagen bio stimulation in zone 3 with a vector system using (REVERSAL) which is a CE certified product based on polylactic acid (PLA) that stimulates the synthesis of collagen and hyaluronic acid. Finally, a lip moisturizer with non-cross-linked hyaluronic acid. It was indicated to change some of her veneers because they were defective and the placement of invisible orthodontics after the radiological study. To conclude, 3-month maintenance was recommended with dermal redensification and facial adipostructure to maintain her structures.

Discussion and Conclusion

The new image of dentistry, orofacial harmonization, opens up new horizons for solving cases that would have limited results with interventions restricted to traditional dentistry. Therefore, by understanding that, in addition to the teeth and gums, the lips and facial muscles also participate in the esthetics of the smile, it is possible to broaden the diagnosis and the range of treatments to achieve the best results. For this reason, dentistry today is concerned with the health and well-being of the client-patient as a whole and more than just treating the dental elements, they are also interested in restoring balance and proportion to the face, body and mind.

Therefore, considering dynamization strategies, including the teledontology tool within the facial analysis provides relevance within the planning of a treatment that involves its aesthetics; since it allows us to evaluate factors that influence the interpretation and success of the results to be achieved without neglecting factors such as age, race, sex, body habitus and personality of the individual [12].

In fact, the use of the DENTAL APP evidenced through the photographic record clinical findings that showed obvious changes, so that, when performing the respective clinical analysis of the facial thirds and the conditions of the oral cavity conditioned the professional to understand that suggesting multiple therapies would make achieve a more natural appearance. That is to say that the correct choice of procedures benefited the client-patient, thus achieving an intelligent orofacial beauty that is defined as the harmonious and symmetrical balance that is provided to the complex organs integrating the orofacial system as the nervous, anatomical and physiological unit that is located in the cervicofacial skull.

Territory constituted by its different structures, which will make it possible to achieve large doses of perfection based on the stimulation of the cellular rhythm by means of intelligent products and technologies that are both minimally invasive and multifunctional in order to combat the causes of aging under a philosophy based on prevention, correction and preservation [13].

Finally, it should be noted that the tool made it possible to verify that it generates accessibility to information, which promotes mutual feedback (client-patient and dentist/dentist and client-patient), in addition to complementing the diagnosis and future treatment plan by acting as an information service. Finally, ultimate success requires a series of well-planned actions that together with holistic dentistry provide the comprehensive understanding to obtain wellness, function and esthetics with all areas of the orofacial system². In effect, harmonization represents a complement to promote health, beauty,

self-esteem and the consequent change in the life of the client-patient, that is, we have in our hands the power to awaken or establish a new way of life within each one of them.

Ethical Responsibility

Data confidentiality: the author declares that she has followed the protocols of her work center on the publication of client-patient data, and therefore, they have received sufficient information and have given their written informed consent to participate in this study.

Conflict of Interest

The author declares that she does not have any type of interest.

References

1. Herrera A and Aguirre N (2021) Management of the Dental Client-Patient as a Dimension of Relational Capital. *Milestones of Economic and Administrative Sciences*. 27(79): 345-370.
2. Lobo M (2020) Orofacial Harmonization based on Visages and Facial Analysis. In C. & Collaborators, *Orofacial Harmonization Clin. Case*. 1: 133-160. Bogota, Colombia: Amolca.
3. Largura L, Ubaldó M, and Martins PA (2020) Ristow's space. Key point in the treatment of the midface. In A. Carbone, & Collaborators, *Orofacial Harmonization. Clin. Case*. 1:106-132. Bogota: Amolca.
4. Ministry DS (2009) Secretaria de Vigilancia em Saude. Departamento de Analise de Situacao de Saude Brasil. Retrieved from https://bvsms.saude.gov.br/bvs/publicacoes/saude_brasil_2009.pdf
5. Carbone A, Brito A, Dames TA, et al (2020) *Orofacial Harmonization Clinical Cases Volume 1*. Bogota Colombia: Amolca.
6. Gummesson E (2011) *Total relationship marketing*. Routledge.
7. Marquez V (2020) Teleconsultation in the Coronavirus pandemic: challenges for telemedicine post-COVID-19. *Colombian Rev. Gastroenterology*. 35: 5-16.
8. Arellan AM (2022) Dental App as a Customer Relationship Management (CRM) Strategy for Relational Capital within the Orofacial Harmonization. Arellan, Angela Maria Herrera (2022). *Dental App as a Customer Relationship Management Rev. Int J Dent Med*. 8(1):18-28.
9. James AO and Marakas GM (2006) *Management Information Systems (seventh Ed.)*. Mc Graw Hill.
10. Information Technologies T (2018) *Management information systems*. Retrieved on January 17, 2021, from <https://www.tecnologias-informacion.com/sigerencial.html>
11. Velazco G (2020). FACIAL ADIPOSTRUCTURE. *Acta Bioclinica* 10(20): 25-46.
12. Burgue J (2004) *The face, its aesthetic proportions*. Habana, Cuba: CIMEQ.
13. Herrera A and Soto N (2022) Intelligent orofacial beauty: an epistemic reflection from the Venezuelan dental client. *SCIENCE ergo-sum*. 29(2).

Citation:

Herrera A (2022) Digital Dynamization Strategies in Orofacial Harmonization Clinical Case. *J Dent Maxillofacial Res* Volume 5(2): 1-5.